

This Page Is Inserted by IFW Operations
and is not a part of the Official Record

BEST AVAILABLE IMAGES

Defective images within this document are accurate representations of the original documents submitted by the applicant.

Defects in the images may include (but are not limited to):

- BLACK BORDERS
- TEXT CUT OFF AT TOP, BOTTOM OR SIDES
- FADED TEXT
- ILLEGIBLE TEXT
- SKEWED/SLANTED IMAGES
- COLORED PHOTOS
- BLACK OR VERY BLACK AND WHITE DARK PHOTOS
- GRAY SCALE DOCUMENTS

IMAGES ARE BEST AVAILABLE COPY.

**As rescanning documents *will not* correct images,
please do not report the images to the
Image Problem Mailbox.**

STIC-ILL

8/05/14

From: Canella, Karen
Sent: Wednesday, May 14, 2003 3:05 PM
To: STIC-ILL
Subject: ill order 09/230,955

445784

Art Unit 1642 Location 8E12(mail)

Telephone Number 308-8362

Application Number 09/230,955

1. American Journal of Pathology:
1993 Feb, 142(2):403-412
1993, 143(4):1150-1158
1984, 114(3):454-460
1996, 148(3):865-875
1965 Sep, Vol. 44, pp. 280-282
2. Cancer Research, 1993 May 15, 53(10 suppl):2287-2299
3. Cancer epidemiology, biomarkers and Prevention, 1996 Jul, 5(7):549-557
4. Lab Investigation:
1980, 42(1):91-96
1988, 58(2):141-149
5. Gynecol Oncol, 1982, 13(1):58-66
- * 6. International Journal of Gynecological Pathology:
1985, 4(4):300-313
1986, 5(2):151-162
1992, 11(1):24-29
7. Differentiation:
1986, 31(3):191-205
1988, 39(3):185-196
8. Cancer (Phila), 1989, 63(7):1337-1342
9. Cancer Res, 1990, 50(16):5143-5152
10. Virchows Arch B Cell Pathol Incl Mol Pathol, 1987, 54 (2):98-110
11. Acta Histochemica et Cytochemica:
1994, 27(3):251-257
1996, 29(1):51-56
12. Archives of Gynecology and Obstetrics, 1989, 246(4):233-242
13. Clin Lab Med, 1995 Sep, 15(3):727-742
14. Clin Obstet Gynaecol, 1984 Apr, 11 (1):5-23

RECEIVED

1655054

Immunohistochemical Identification of Langerhans Cells in Normal Epithelium and in Epithelial Lesions of the Uterine Cervix

Jo J. G. Puts, Olof Moesker, Rob M. W. de Waal, *Peter Kenemans, G. Peter Vooijs, and Frans C. S. Ramaekers

*Department of Pathology and *Institute of Obstetrics and Gynecology, St. Radboud Hospital, University of Nijmegen, The Netherlands*

Summary: Using the double label indirect immunofluorescence technique we have studied vimentin-positive cells present in normal ecto- and endocervical epithelium, subcolumnar reserve cell hyperplasia, and squamous metaplastic and dysplastic epithelium of the uterine cervix. Monoclonal antibodies to Ia- and T6-antigens were applied in the examination of the expression of these membrane markers by such cells. Our studies reveal the presence of a relatively large number of vimentin-positive and T6-positive (Langerhans) cells in normal ectocervical stratified squamous epithelium, a small number in endocervical columnar epithelium, and a larger number in subcolumnar reserve cell hyperplasia and in immature squamous metaplasia. In this respect, mature squamous metaplastic epithelium shows a great resemblance to normal ectocervical stratified squamous epithelium. In contrast with previous reports in the literature we could only demonstrate small numbers of Langerhans cells in cases of dysplasia. The clinicopathological significance of these findings is discussed. **Key Words:** Uterine cervix—Langerhans cells—Vimentin—Ia-antigens—T6-antigen—Immunohistochemistry.

In a recent study (1) we described the expression of the intermediate filament proteins cytokeratin and vimentin in normal epithelium and in neoplastic epithelial lesions of the uterine cervix. It was found that cytokeratin occurred exclusively in epithelial cells. Vimentin was found in stromal cells as well as in some dendritic-shaped cells lying between the epithelial cells. These cells were negative for cytokeratin and showed a distribution and morphology similar to those observed for vimentin-positive dendritic cells in human epidermis (2). Many of the vimentin-positive cells in human epidermis could be identified as Langerhans cells (LC), and it was concluded that these epidermal LC contain intermediate filaments of the vimentin type (3). Similar results have been obtained by Löning et al. (4) and Mahrle et al. (5).

The aim of the present study was to determine whether the vimentin-positive

Address correspondence and reprint requests to Dr. F. C. S. Ramaekers at Dept. of Pathology, University of Nijmegen, Geert Grooteplein Zuid 24, 6525 GA Nijmegen, The Netherlands.

cells present in various conditions of the epithelium of the uterine cervix could also be identified as LC and if marked differences in their occurrence among these epithelia could be observed.

Experimental data in murine models have indicated that epidermal LC are derived from cells originating in the bone marrow (6). The presence of vimentin in epidermal LC points to a mesenchymal origin of LC, which supports their suggested bone marrow origin (3-5). The demonstration of the common leukocyte antigen on epidermal LC provides additional evidence for this idea (7).

LC belong to a family of antigen-presenting cells (APC) (8). These APC are required for the initial uptake and processing of antigens in order to present immunologically relevant moieties to T-lymphocytes, and so LC assume a key role in the afferent limb of the immune response (for a review on LC see ref. 9). LC possess receptors for the Fc portion of IgG and several complement components and can be stained by antibodies against class II (Ia) antigens of the major histocompatibility complex (MHC) (9). The presence of class II MHC antigens on the surface of LC is essential for the induction of T-lymphocyte responses (8). Class II MHC antigens, however, also can be expressed by epidermal keratinocytes under certain conditions and by a wide variety of infiltrating inflammatory cells such as B-lymphocytes, some activated T-lymphocytes, and mononuclear phagocytes (10).

From several recent reports (11-14) it has emerged that T6-antigen (a membrane antigen of normal thymocytes) appears to be superior to Ia-antigens as a marker for LC in normal and diseased epidermis. T6-antigen is also encountered on so-called indeterminate cells (13), which are identifiable only by electron microscopy (15). These cells are present in small numbers in both the epidermis and the dermis and are ultrastructurally similar to LC, although they do not contain Birbeck granules (7). At present, indeterminate cells are considered to be precursors of LC (7,11,13,16). According to Murphy (13), it appears that monoclonal anti-T6 antibody is both a specific and a sensitive probe for LC and indeterminate cells in the skin. In this report we will use the term LC for both Langerhans cells and indeterminate cells, since these cells cannot be distinguished immunohistochemically.

A brief review of the few reports which have appeared on studies of LC in cervical epithelium has been presented by Morris et al. (17; for more recent studies see refs. 18-21). In recent studies, widely divergent methods for identification of LC in the uterine cervix have been used, such as the application of monoclonal or conventional antibodies, the demonstration of membrane ATPase activity, and the performance of zinc-iodide-osmium procedures. Morris et al. (17) and Caorsi and Figueroa (21) have emphasized the close interaction between LC and T-lymphocytes in cervical tissue, suggesting an important role of LC in local immune responses in the uterine cervix. According to Bjercke et al. (19), 1-3% of all cells in normal ectocervical stratified squamous epithelium are dendritic cells.

Several authors (18,20,21) have noticed an increase in the number of LC in cervical epithelium showing characteristics of cervical intraepithelial neoplasia (CIN), but the conclusions were based on small series.

The material described in this article covers a relatively large series of tissue

specimens from the uterine cervix, including normal, hyperplastic, metaplastic, and dysplastic.

In double label immunofluorescence

1. excluding a possible role of vimentin in the epithelium
2. establishing the relationship between LC and keratinocytes in these epithelia
3. defining the cells by Ia- and/or T6-antigen
4. making an appropriate comparison with cells present in normal epithelium
5. finding out whether the number of LC is higher than vimentin-positive cells

The tissue specimens (1) and are summarized in Table 1. The material includes 100 normal, 100 hyperplastic, 100 metaplastic, and/or squamous epithelia in which no dysplasia and in situ carcinoma were found in biopsies that had been taken for diathermic stripping. Among the specimens 100 mild dysplasia (CIN I), 100 moderate dysplasia (CIN II), and 100 severe dysplasia (CIN III) were presented in the material.

Frozen parallel sections were made for double label immunofluorescence staining and for double label immunohistochemistry. Selection from these sections was made on the basis of serum and Ia-monoclonal antibody respectively.

The sections used were fixed in Bouin's solution for 2 h, dipped in 70% ethanol, -20°C. They were then cleared in cedarwood oil, air-drying for 30 min, and cleared in cedarwood oil, buffered saline, pH 7.4, for 30 min. The double label immunofluorescence technique. Details of the technique are given in (22). The following procedure was used:

1. An affinity purified anti-Ia-antibody (1:1000) was used for the detection of Ia-antigen. For preparation of the anti-Ia-antibody see (23).
2. An affinity purified anti-T6-antibody (1:1000) was used for the detection of T6-antigen. The anti-T6-antibody was prepared from calf lens by the method of Murphy (13). Testing have been done

the uterine cervix could
their occurrence among

at epidermal LC are de-
presence of vimentin in
which supports their sug-
the common leukocyte
this idea (7).

(C) (8). These APC are
in order to present im-
LC assume a key role
on LC see ref. 9). LC
complement components
ligands of the major his-
s II MHC antigens on
phocyte responses (8).
by epidermal keratino-
infiltrating inflammatory
ytes, and mononuclear

at T6-antigen (a mem-
rior to Ia-antigens as a
gen is also encountered
le only by electron mi-
both the epidermis and
igh they do not contain
considered to be pre-
appears that monoclonal
r LC and indeterminate
r both Langerhans cells
anguished immunohisto-

ed on studies of LC in
l. (17; for more recent
nt methods for identifi-
h as the application of
n of membrane ATPase
cedures. Morris et al.
use interaction between
mportant role of LC in
to Bjercke et al. (19),
us epithelium are den-

i the number of LC in
ntraepithelial neoplasia

y large series of tissue

specimens from the uterine cervix, representing a great variety of normal, hyperplastic, metaplastic, and dysplastic conditions of cervical epithelium.

In double label indirect immunofluorescence experiments we have focused on

1. excluding a possible overlap between the expression of cytokeratin and vimentin in the epithelia of the uterine cervix,
2. establishing the presence of vimentin-positive dendritic and nondendritic cells in these epithelia and their respective expression of membrane markers as defined by Ia- and/or T6-monoclonal antibodies,
3. making an approximate comparison of the number of Ia- and/or T6-positive cells present in normal epithelia and epithelial lesions of the uterine cervix, and
4. finding out whether Ia- and/or T6-monoclonal antibodies react with other than vimentin-positive cells.

MATERIALS AND METHODS

The tissue specimens used in this study were collected as previously described (1) and are summarized in Table 1. Briefly, tissue specimens showing normal ectocervical and endocervical epithelia, subcolumnar reserve cell (SRC) hyperplasia, and/or squamous metaplasia were obtained from hysterectomy specimens in which no dysplastic or neoplastic epithelial lesions were present. Dysplastic and in situ carcinomatous (CIS) epithelial lesions were studied in cervical biopsies that had been taken under colposcopic control, using a steel wire loop for diathermic stripping after the application of acetic acid (3%) and iodine solution. Among the specimens showing dysplasia, epithelial lesions ranging from mild dysplasia (CIN 1) to severe dysplasia-CIS (CIN 3) were represented. Criteria for diagnosis have been described previously (1). Photomicrographs of hematoxylin and eosin (H & E)-stained sections of representative epithelial lesions were presented in this report (1).

Frozen parallel sections 4-7 μ m thick from all specimens were used for H & E staining and for double labeling with keratin and vimentin antibodies. A random selection from these specimens was made for double labeling with vimentin antiserum and Ia-monoclonal antibody and vimentin antiserum and T6-monoclonal antibody respectively, as shown in Table 1.

The sections used for immunohistochemistry were air-dried (room temperature, 2 h), dipped in acetone (room temperature, 5-10 s) and stored overnight at -20°C. They were then again air-dried (room temperature, 1 h) and fixed in methanol (-20°C, 5-10 min) and acetone (room temperature, 10-30 s). After air-drying for 30 min at room temperature, they were rehydrated in phosphate-buffered saline, pH 7.4 (2 \times 5 min) and incubated for the indirect immunofluorescence technique. Double labeling procedures have been described previously (22). The following primary antibody preparations were used in this study:

1. An affinity purified polyclonal rabbit antiserum directed against human skin keratins. For preparation and specificity testing see Ramaekers et al. (2,23-26).
2. An affinity purified polyclonal rabbit antiserum raised against vimentin isolated from calf lens by preparative gel electrophoresis. Preparation and specificity testing have been described previously (2,23-26).

TABLE 1. Immunohistochemical findings with Langerhans cells under various conditions of the epithelium of the uterine cervix

	Number of specimens	Number of vimentin-positive cells	Dendritic morphology recognizable	Number of specimens incubated with OKIa 1/OKT6	Dendritic OKIa 1-positive cells	Nondendritic OKIa 1-positive cells	Dendritic OKT6-positive cells	Nondendritic OKT6-positive cells
Ectocervical stratified squamous epithelium	11	++++	Frequently	9	++++	+++	++++	sp/+
Endocervical columnar epithelium	13	sp/+	Not convincingly	8	-	sp/+	-	sp/-
SRC hyperplasia and immature squamous metaplasia	10	sp/+	Not convincingly	5	-	sp/+	-	sp
Mature squamous metaplastic epithelium	10	++++	Frequently	7	++++	+++	++++	+++
Dysplastic epithelium/CIS	32 ^a	sp/+++	Variable	11 ^b	sp/+++	sp/++	sp/-	sp/-

+++ +, large number; ++, moderate number; +, small number; sp, sporadically; -, not present; SRC, subcolumnar reserve cell; CIS, carcinoma in situ.
^a These specimens included: mild dysplasia (3x); mild-moderate dysplasia (3x); moderate-severe dysplasia (14x); severe dysplasia (6x); severe dysplasia-CIS (6x).
^b These specimens represented: mild dysplasia (3x); mild-moderate dysplasia (2x); moderate-severe dysplasia (2x); severe dysplasia (2x).

3. A mouse monoclonal antibody (B.V., Apeldoorn, The Netherlands).
4. A mouse monoclonal antibody (Pharmaceutical Corporation).
5. A mouse monoclonal antibody (Pharmaceutical Corporation).

As second antibodies, rabbit IgG (Nordic Immunology AB, Umeå, Sweden), goat anti-sheep F(ab')₂ (Cappel, MA, U.S.A.) were used. All were checked using tissue sections with the second antibody.

In all cases that were checked with the key antibody, dendritic and nondendritic cells were present. The results of the immunohistochemical reactions with vimentin and OKT6 were as follows:

Normal ectocervical squamous epithelium
 In general this type of epithelium contains many vimentin-positive cells, although the number varies.

Most of the dendritic cells are OKT6-positive.

Nondendritic vimentin-positive cells are OKT6-negative. Some vimentin-positive cells are OKT6-positive.

The ratio between vimentin-positive and OKT6-positive cells varies. In the ectocervical squamous epithelium, vimentin is present. These were OKT6-negative. In the endocervical columnar epithelium, vimentin is present. These were OKT6-negative.

No reaction with OKT6 was seen.

Normal endocervical columnar epithelium
 Between the columnar cells, many vimentin-positive cells could be seen, while about 10% of the cells were OKT6-negative.

In all specimens OKT6-positive cells were present.

Just beneath or at the surface of the columnar cells, vimentin-positive cells were found. In the endocervical columnar epithelium, vimentin is present. These were OKT6-negative.

3. A mouse monoclonal antibody to calf lens vimentin, (Euro-Diagnostics B.V., Apeldoorn, The Netherlands).

4. A mouse monoclonal antibody to human DR-framework (OKIa 1; Ortho Pharmaceutical Corporation, Raritan, NJ, U.S.A.).

5. A mouse monoclonal antibody to human thymocyte (OKT6; Ortho Pharmaceutical Corporation).

As second antibodies, fluorescein isothiocyanate (FITC) conjugated goat anti-rabbit IgG (Nordic Immunology, Tilburg, The Netherlands) and Texas Red conjugated sheep F(ab')₂ anti-mouse Ig (New England Nuclear, St. Albany, Boston, MA, U.S.A.) were used. Overlap between the FITC and Texas Red channels was checked using tissue sections labeled with a single second antibody. Incubations with the second antibodies alone were used as negative controls.

RESULTS

In all cases that were examined with the intermediate filament antibodies no reaction with the keratin antiserum was seen in nonepithelial vimentin-positive dendritic and nondendritic cells.

The results of the double label experiments using combinations of either the polyclonal vimentin antiserum and OKIa 1 or the polyclonal vimentin antiserum and OKT6 were as follows (see also Table 1).

Normal ectocervical stratified squamous epithelium (Fig. 1a, b, c)

In general this type of epithelium showed a relatively large number of vimentin-positive cells. Dendritic morphology was recognizable in each specimen although the number of dendritic cells was variable.

Most of the dendritic vimentin-positive cells were also positive for OKIa 1 and/or OKT6.

Nondendritic vimentin-positive cells generally were OKIa 1-positive and OKT6-negative. Some OKIa 1-negative and some OKT6-positive nondendritic vimentin-positive cells were seen.

The ratio between OKIa 1-positive and OKT6-positive cells was variable.

In the ectocervical stroma a fairly large number of OKIa 1-positive cells was present. These were frequently found just beneath or at the squamous epithelial-stromal border. In one specimen a few OKT6-positive cells were observed in this region.

No reaction with OKIa 1 or OKT6 was seen in the squamous epithelial cells.

Normal endocervical columnar epithelium (Fig. 1d, e, f)

Between the columnar epithelial cells of the endocervix only a few vimentin-positive cells could be found. None of these cells showed a convincingly dendritic shape, while about half of the cells were OKIa 1-positive. In general the cells were OKT6-negative. In several cases, however, a few OKT6-positive cells were seen.

In all specimens OKIa 1-positive cells were found at a higher frequency than OKT6-positive cells.

Just beneath or at the epithelial-stromal border a variable number of OKIa 1-positive cells was found. OKT6-positive cells could not be demonstrated in this region.

in situ:
 a These specimens included: mild dysplasia (3 x); mild-moderate dysplasia (3 x); moderate-severe dysplasia (14 x); severe dysplasia (6 x); severe dysplasia-CIS (6 x).
 b These specimens represented: mild dysplasia (3 x); mild-moderate dysplasia (2 x); moderate-severe dysplasia (2 x); severe dysplasia (2 x); severe dysplasia-CIS (2 x).

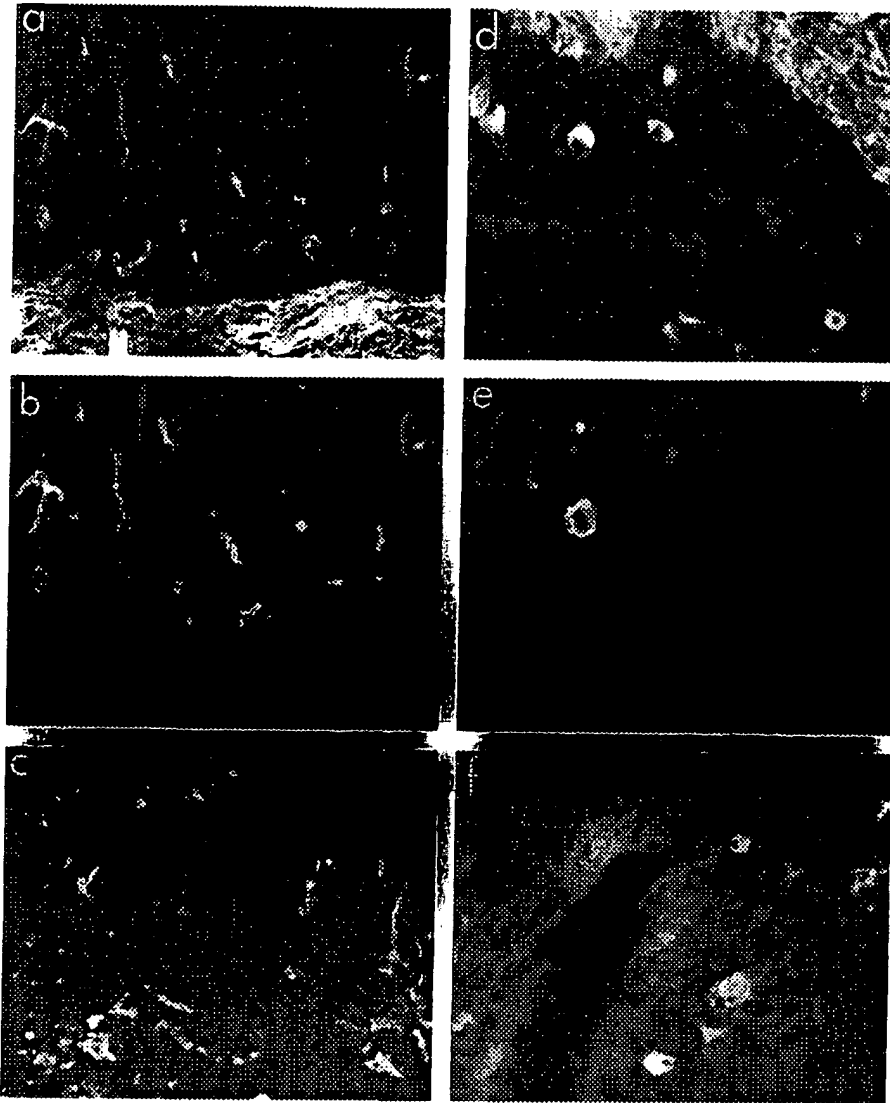


FIG. 1. Double label immunofluorescence (a and b, d and e) and immunofluorescence (c, f) photomicrographs of identical and corresponding areas respectively, showing reactions in ectocervix (a-c) and in endocervix (d-f). a-c: Normal ectocervical stratified squamous epithelium; note comparable numbers of positively staining dendritic and nondendritic cells in the epithelium with all sera used. d-f: Endocervical cleft showing both columnar epithelium and subcolumnar reserve cell hyperplasia; note a varying number of positively staining nondendritic cells in the epithelia with the different sera used. (a and d) Incubated with polyclonal anti-vimentin antiserum; (b and e) incubated with OKT6; (c and f) incubated with OKIa 1; note also OKIa 1-positive cells in the stroma. (a-c, $\times 145$; d, e, $\times 270$; f, $\times 340$).

Int J Gynecol Pathol, Vol. 5, No. 2, 1986

INTERNATIONAL SOCIETY OF
GYNCOLOGICAL PATHOLOGISTS

International Journal of Gynecological Pathology

Please enter my subscription to the INTERNATIONAL JOURNAL OF GYNECOLOGICAL PATHOLOGY, Vol. 5, 1986. Published quarterly.

- Individual: \$89.00 per year, U.S. \$99.00 per year, elsewhere.
 (Personal rates are not applicable if payment is to be made through an institution.)
 Institution: \$125.00 per year, U.S.; \$135.00 per year, elsewhere.
 New Renewal
 Please bill me at address below.

or OKT6-positive ex-
planation for this find-

In some specimens
whereas in other spe-

Just beneath or at
were seen. Sporadic

In one specimen a
observed in mature s-

Dysplastic epithelium

When comparing (c
reactivity between the
bodies.

The number of vimentin
but usually not more

Dendritic morphology
some specimens it oc-

About 50% of the
while OKT6-positive

It was remarkable to find that some columnar epithelial cells were both cytokeratin- and vimentin-positive. This coexpression of different types of intermediate filament proteins seemed to occur more frequently in the direction of the uterine isthmus. This phenomenon will be the subject of future studies.

In several specimens variable numbers of columnar epithelial cells reacted weakly or, in a single case, strongly with OKIa 1, but not with OKT6.

Subcolumnar reserve cell hyperplasia (Fig. 1d, e, f) and immature squamous metaplasia

As in the endocervical columnar epithelium, in these types of epithelium also only a few vimentin-positive cells were seen, while again a convincingly dendritic shape was not recognized. About half of these cells were OKIa 1-positive. Although still sparse, a slightly larger number of OKT6-positive cells was found in comparison to the endocervical columnar epithelium.

OKIa 1-positive cells were present at a higher frequency than OKT6-positive cells in all specimens.

Also in these cases OKIa 1-positive cells were found in proximity to the epithelial-stromal border, and in a single case a sporadic OKT6-positive cell could be demonstrated in this region.

In one specimen a weak positive reaction with OKIa 1, but not with OKT6, was seen in immature squamous metaplastic epithelium.

Mature squamous metaplastic epithelium (Fig. 2a, b, c)

A relatively large number of vimentin-positive cells was demonstrable in mature squamous metaplastic epithelium. Cells with a dendritic morphology could be recognized in each specimen, but the number of dendritic cells varied. Dendritic vimentin-positive cells were mostly OKIa 1- and/or OKT6-positive.

A large proportion of the nondendritic vimentin-positive cells was OKIa 1-positive and quite a number of these cells was OKT6-positive.

In these cases a significant number of dendritic and nondendritic OKIa 1- and/or OKT6-positive cells appeared to be vimentin-negative. We have no clear explanation for this finding.

In some specimens OKIa 1-positive cells outnumbered OKT6-positive cells, whereas in other specimens the opposite appeared to be the case.

Just beneath or at the epithelial-stromal border many OKIa 1-positive cells were seen. Sporadically an OKT6-positive cell was present in this region.

In one specimen a weak positive reaction with OKIa 1, but not with OKT6, was observed in mature squamous metaplastic epithelial cells.

Dysplastic epithelium (Fig. 2d, e, f)


When comparing the different degrees of dysplasia, no significant difference in reactivity between the tissues was noted with vimentin, OKIa 1, or OKT6 antibodies.

The number of vimentin-positive cells in the different specimens was variable, but usually not more than a small to moderate number of these cells was seen. Dendritic morphology was recognized infrequently in most cases, although in some specimens it occurred quite often.


About 50% of these dendritic vimentin-positive cells were OKIa 1-positive, while OKT6-positive dendritic cells were found only sporadically.

POSTAGE WILL BE PAID BY ADDRESSEE

FIRST CLASS
BUSINESS REPLY MAIL
PERMIT NO. 181
MAHOPAC, N. Y.



NO POSTAGE
NECESSARY
IF MAILED
IN THE
UNITED STATES



fluorescence (c, f) photomicrographs in ectocervix (a-c) epithelium; note comparable epithelium with all sera used. (d, e) reserve cell hyperplasia; (f) metaplasia with the different sera (c, f) incubated with OKT6; (c, f) incubated with OKIa 1. (a-c, ×145; d, e, ×270;

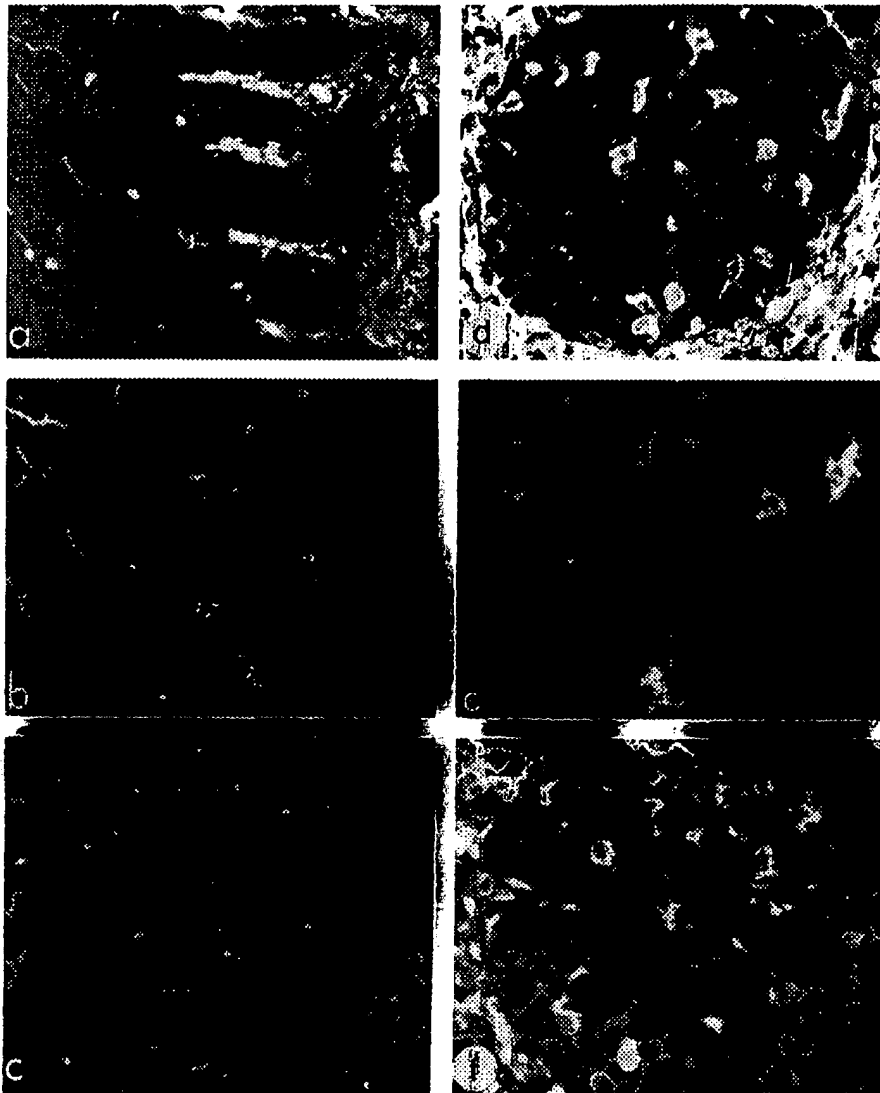


FIG. 2. Double label immunofluorescence (a and b, d and e) and immunofluorescence (c and f) photomicrographs of identical and corresponding areas respectively, showing reactions in squamous metaplastic (a-c) and dysplastic epithelium (d-f). a-c: Mature squamous metaplastic epithelium covering the surface in the endocervix; note comparable numbers of positively staining cells in the epithelium with all sera used. d-f: Severe dysplasia-CIS within endocervical cleft; note a varying number of positively staining cells in the epithelium with the different sera used. (a and d) Incubated with polyclonal anti-vimentin antiserum; (b and e) incubated with OKT6; (c and f) incubated with OKIa 1; note also OKIa 1-positive cells in the stroma; in (f) several OKIa 1-positive epithelial cells are present. (a and b, $\times 145$; c, $\times 130$; d-f, $\times 230$).

A moderate number of OKT6 positive dendritic cells.

Strikingly, in these plastic epithelium were lying the surface. In the 1-positive cells outside the epithelial-stromal border.

Focally a weak positive reaction was observed in dysplastic epithelium.

Whenever normal epithelium was present in the specimens a stratified squamous epithelium was observed.

The identification of these cells cannot be recognized because they are known to contain vimentin antibodies. This is a uterine cervix. This cervical tissue specimen is specifically derived from the mesenchymally derived cells and T6 for the immunofluorescence reactions of antisera have been used (3-5) and in oral mucosa.

In addition to the OKIa 1-positive cells in the epithelium, OKIa 1-positive cells in the stroma were present.

These relatively large cells were present in the epithelium and may represent hugging cells. These hugging cells act as an intermediate cell type between T-lymphocytes and epithelial cells in pathologic processes.

The presence of these cells in the cervical squamous epithelium has been described before by M...

Since Ia-antigens are present in the epithelium and T6 in double label immunofluorescence in the uterine cervix. In the normal ectocervical epithelium and dysplastic epithelium, the immunofluorescence reaction in the epithelium was very

A moderate number of nondendritic vimentin-positive cells were OKIa 1-positive, while OKT6 positivity was found here at a slightly higher frequency than in dendritic cells.

Strikingly, in these specimens it was easier to find OKT6-positive cells in dysplastic epithelium within endocervical clefts than in dysplastic epithelium covering the surface. In some cases not one OKT6-positive cell was present. OKIa 1-positive cells outnumbered OKT6-positive cells in all specimens. Many OKIa 1-positive and sporadic OKT6-positive cells were seen in close proximity to the epithelial-stromal border.

Focally a weak positive reaction with OKIa 1, but not with OKT6, was observed in dysplastic epithelial cells.

Whenever normal ectocervical stratified squamous epithelium was present in the specimens a staining pattern was found identical to that described in ectocervical stratified squamous epithelium in specimens without concomitant dysplasia.

DISCUSSION


The identification of LC requires the application of special techniques since they cannot be recognized as such in conventional light microscopy. Because LC are known to contain intermediate filaments of the vimentin type (3-5), we have used vimentin antibodies to demonstrate these cells in various epithelia of the uterine cervix. This method served as an indicator of the occurrence of LC in cervical tissue specimens. Vimentin, however, is also found in many other mesenchymally derived cells. Therefore, we have used monoclonal antibodies to Ia and T6 for the immunohistochemical recognition of LC, since similar combinations of antisera have been used previously for the identification of LC in skin (3-5) and in oral mucosa (4).

In addition to the presence of OKIa 1-positive dendritic and/or nondendritic cells in all epithelia examined, we have also found a varying number of OKIa 1-positive cells in the subepithelial stroma in proximity to the epithelial-stromal border.

These relatively large vimentin-positive/OKIa 1-positive (and OKT6-negative) cells were present in the neighborhood of and among mononuclear inflammatory cells and may represent so-called hugging cells as described by Morris et al. (17). These hugging cells have been suggested to represent tissue macrophages and to act as an intermediate step in the transfer of antigenic information from LC to T-lymphocytes. Further investigations are required to determine their exact role in pathologic processes in the uterine cervix.

The presence of Ia-antigens in cervical epithelial cells other than normal ectocervical squamous cells, as demonstrated in some of our cases, has been described before by Morris et al. (18). Its significance, however, is not clear.

Since Ia-antigens are not restricted to LC, we have used antibodies to vimentin and T6 in double label experiments for the identification of LC in epithelia of the uterine cervix. In this way we have found a relatively large number of LC in normal ectocervical stratified squamous epithelium and in mature squamous metaplastic epithelium. The immunofluorescence pattern in both types of cervical epithelium was very similar, although in mature squamous metaplastic epithelium



fluorescence (c and f) photo-reactions in squamous metaplastic epithelium covering lining cells in the epithelium (t; note a varying number of and d) Incubated with poly-incubated with OKIa 1; note epithelial cells are present. (a

a relatively larger number of nondendritic OKT6-positive cells was present. These nondendritic OKT6-positive cells may also represent LC (14).

Between the columnar epithelial cells of the endocervix only a few OKT6-positive cells were seen. They did not show a convincing dendritic shape but, as mentioned before, this may not be obligatory for a positive identification as LC. As far as we could verify, the occurrence of LC between endocervical columnar epithelial cells has so far not been described in the literature. However, their presence among columnar epithelial cells in main pancreatic ducts of the cat has been demonstrated by Böck (27).

The immunofluorescence pattern in SRC hyperplasia and immature squamous metaplasia showed many similarities to the pattern seen in endocervical columnar epithelium, in that small numbers of vimentin-positive cells and only a few OKT6-positive cells were found, all lacking a convincing dendritic shape.

In dysplastic epithelial lesions, a rather small to moderate number of vimentin-positive cells was generally present. OKT6-positive cells were found only sporadically in these lesions, or not at all, indicating the presence of only small numbers of LC in our cases of dysplasia. This finding is in contrast with earlier data from the literature (18,20,21) in which an increase of LC in dysplastic epithelial lesions as compared to normal ectocervical stratified squamous epithelium has been described. Methodological aspects may account for these differences. MacLean (20) demonstrated LC using a histochemical technique for adenosine triphosphatase, while Caorsi and Figueroa (21) applied zinc-iodide-osmium procedures. The method used by Morris et al. (18) closely resembles our approach, differing mainly in the antibodies and the immunohistochemical detection method applied. Also, sampling artifacts cannot be excluded since, as indicated above, relatively small series have been presented by these authors.

In a further attempt to explain this discrepancy, several possibilities may be considered. In the first place, factors inherent to biopsy collection or processing may destroy or alter T6 antigenic determinants on the surface of LC. This seems unlikely, however, since normal ectocervical stratified squamous epithelium present in biopsies of dysplastic epithelial lesions showed a similar number of LC as the ectocervix of specimens lacking dysplasia. As an alternative explanation, the T6 antigenic determinants on the surface of LC may have been altered because of the dysplastic process itself. Finally, the dysplastic process may have prevented a major number of LC from entering the epithelium or may have caused the disappearance of LC formerly present. Any or all of these factors may have been of greater importance for dysplastic epithelium at the surface than for dysplastic epithelium in endocervical clefts. In this case the dendritic vimentin-positive and OKT6-negative cells in the dysplastic lesions may have represented other members of the family of APC.

The detection of sporadic OKT6-positive cells in proximity to the epithelial-stromal border in different cervical tissue specimens is consistent with known kinetic properties of LC.

Using standard surgical techniques and a standard procedure for tissue processing, a variable number of vimentin-positive cells was found in the 32 cases of dysplastic lesions, meaning that dysplastic lesions with relatively few of these cells occur in addition to dysplastic lesions containing larger populations of them. It should be kept in mind that these vimentin-positive cells may represent LC as

well as other types of LC in local immune response in malignant disease. The number and nature of these lesions may be a plastic lesion. This is a dynamic process, but may be reversible.

Although Murphy (20) has questioned the significance of pathologic processes correlating number of LC in these lesions based on his experience to clinicians and pathologists, it will show regression in some cases. It is conceivable that such a regression may be from future studies with greater reliability.

Acknowledgment: We are grateful to Drs. J. J. G. Puts and G. J. G. Lang for their contributions as residents in the Department of Gynecology and Obstetrics, and to Dr. J. J. G. Puts for his acknowledgment for excising the specimens for typing the manuscript. Queen Wilhelmina Fu

1. Puts JJG, Moesker J. Early neoplastic epithelium. *Am J Surg* 1983;71:635-43.
2. Ramaekers FCS, Puts JJG. Malignant melanoma. *Am J Surg* 1983;71:635-43.
3. De Waal RMW, Seiler HJ. Skin contain intermediate cells. *Dermatol* 1984;82:66.
4. Löning T, Caselitz J. Simultaneous use of sera for immunofluorescence in epidermis and their derivatives. *Am J Surg* 1983;71:635-43.
5. Mahrle G, Bolling G. Type in human epidermis. *Am J Surg* 1983;71:635-43.
6. Katz SI, Tamaki K. Bone marrow. *Nature* 1983;71:635-43.
7. Murphy GF. Cell markers. *Am J Surg* 1983;71:635-43.
8. Poulter LW. Antigenic determinants. *Clin Exp Immunol* 1983;71:635-43.
9. Wolff K, Stingl G. T cells. *Am J Surg* 1983;71:635-43.
10. Barclay AN, Mason DM. Immunological stimulation. *Am J Surg* 1983;71:635-43.
11. Harrist TJ, Muhlbauer H. A marker for Lange cells. *J Invest Dermatol* 1983;71:635-43.
12. Dubertret L, Picardet L. Picardet's cells in neoplasia. *Am J Surg* 1983;71:635-43.
13. Murphy GF. Monoclonal antibodies. *Am J Surg* 1983;71:635-43.
14. De Panfilis G. ATPase activity. *Am J Surg* 1983;71:635-43.
15. Lever WF, Schaumburg-Lenormand P. 1983.

ive cells was present.
nt LC (14).

only a few OKT6-posi-
dendritic shape but, as
ve identification as LC.
endocervical columnar
ature. However, their
tic ducts of the cat has

nd immature squamous
endocervical columnar
: cells and only a few
dendritic shape.

ite number of vimentin-
vere found only sporad-
: of only small numbers
t with earlier data from
lastic epithelial lesions
pithelium has been de-
ferences. MacLean (20)
nosine triphosphatase,
nium procedures. The
ur approach, differing
ection method applied.
icated above, relatively

al possibilities may be
ollection or processing
face of LC. This seems
squamous epithelium
a similar number of LC
lternative explanation,
have been altered be-
stic process may have
ithelium or may have
all of these factors may
at the surface than for
the dendritic vimentin-
may have represented

imity to the epithelial-
consistent with known

cedure for tissue pro-
ound in the 32 cases of
relatively few of these
er populations of them.
s may represent LC as

well as other types of APC. Considering the supposed role of LC and other APC in local immune responses in the uterine cervix (17,21) and their possible involvement in malignant conditions in the female genital tract (19), this variation in number and nature of APC may correlate with the outcome of a particular dysplastic lesion. This may not only be a manifestation of differences in dysplastic processes, but may also reflect differences in host immune responses.

Although Murphy (7) has emphasized that extrapolation of function or sequence of pathologic events from cell numbers is not possible, further studies correlating number and nature of APC in dysplastic lesions with the outcome of these lesions based on long-term follow-up studies may provide useful guidelines to clinicians and pathologists. It is well known that dysplastic lesions occur that will show regression, while others will show a more or less rapid progression. It is conceivable that subtyping dysplastic lesions on the basis of criteria evolving from future studies may perhaps enable us to predict these different outcomes with greater reliability.

Acknowledgment: We thank Drs. W. Willemsen and Ch. Schijf of the Institute of Obstetrics and Gynecology, University of Nijmegen, for providing us with tissue samples; all residents in the Department of Pathology for collecting suitable pieces from the hysterectomy specimens; and Koos Diepenbroek for excellent technical assistance. Wim Janssen is acknowledged for excellent help in preparing the photomicrographs and Yvonne Stammes for typing the manuscript. This work was supported by the Dutch Cancer Foundation, The Queen Wilhelmina Fund, grant no. NUKC 1981-12.

REFERENCES

1. Puts JJG, Moesker O, Kenemans P, Vooijs GP, Ramaekers FCS. Expression of cytokeratins in early neoplastic epithelial lesions of the uterine cervix. *Int J Gynecol Pathol* 1985;4:300-13.
2. Ramaekers FCS, Puts JJG, Moesker O, Kant A, Vooijs GP, Jap PHK. Intermediate filaments in malignant melanomas. Identification and use as marker in surgical pathology. *J Clin Invest* 1983;71:635-43.
3. De Waal RMW, Semeijn JT, Cornelissen IMH, Ramaekers FCS. Epidermal Langerhans cells contain intermediate-sized filaments of the vimentin type: an immunocytologic study. *J Invest Dermatol* 1984;82:602-4.
4. Löning T, Caselitz J, Seifert G, Weber K, Osborn M. Identification of Langerhans cells: simultaneous use of sera to intermediate filaments, T6 and HLA-DR antigens on oral mucosa, human epidermis and their tumours. *Virchows Arch [Pathol Anat]* 1982;398:119-28.
5. Mahrle G, Bolling R, Osborn M, Weber K. Intermediate filaments of the vimentin and prekeratin type in human epidermis. *J Invest Dermatol* 1983;81:46-8.
6. Katz SI, Tamaki K, Sachs DH. Epidermal Langerhans cells are derived from cells originating in bone marrow. *Nature* 1979;282:324-6.
7. Murphy GF. Cell membrane glycoproteins and Langerhans cells. *Hum Pathol* 1985;16:103-12.
8. Poulter LW. Antigen presenting cells in situ: their identification and involvement in immunopathology. *Clin Exp Immunol* 1983;53:513-20.
9. Wolff K, Stingl G. The Langerhans cell. *J Invest Dermatol* 1983;80:17-21s.
10. Barclay AN, Mason DW. Induction of Ia antigen in rat epidermal cells and gut epithelium by immunological stimuli. *J Exp Med* 1982;156:1665-76.
11. Harrist TJ, Muhlbauer JE, Murphy GF, Mihm MC Jr, Bhan AK. T6 is superior to Ia (HLA-DR) as a marker for Langerhans cells and indeterminate cells in normal epidermis: a monoclonal antibody study. *J Invest Dermatol* 1983;80:100-3.
12. Dubertret L, Picard O, Bagot M, et al. Specificity of monoclonal antibody anti-T-6 for Langerhans' cells in normal human skin. *Br J Dermatol* 1982;106:287-9.
13. Murphy GF. Monoclonal anti-T6 antibody and Langerhans cells. *Br J Dermatol* 1982;107:487-9.
14. De Panfilis G. ATP-ase, antigens detected by monoclonal antibodies, ultrastructural characters: which is the best marker for Langerhans cells? *Arch Dermatol Res* 1983;275:407-11.
15. Lever WF, Schaumburg-Lever G. *Histopathology of the skin*. 6th ed. Philadelphia: JB Lippincott, 1983.

16. Hunter JAA. The Langerhans cell: from gold to glitter. *Clin Exp Dermatol* 1983;8:569-92.
17. Morris HHB, Gatter KC, Stein H, Mason DY. Langerhans' cells in human cervical epithelium: an immunohistological study. *Br J Obstet Gynaecol* 1983;90:400-11.
18. Morris HHB, Gatter KC, Sykes G, Casemore V, Mason DY. Langerhans' cells in human cervical epithelium: effects of wart virus infection and intraepithelial neoplasia. *Br J Obstet Gynaecol* 1983;90:412-20.
19. Bjercke S, Scott H, Braathen LR, Thorsby E. HLA-DR expressing Langerhans'-like cells in vaginal and cervical epithelium. *Acta Obstet Gynecol Scand* 1983;62:585-9.
20. MacLean AB. Cervical healing and Langerhans' cells. *Br J Obstet Gynaecol* 1984;91:1145-8.
21. Caorsi I, Figueroa CD. Langerhans cells in squamous exocervical carcinoma: a quantitative and ultrastructural study. *Ultrastruct Pathol* 1984;7:25-40.
22. Ramaekers FCS, Haag D, Kant A, Moesker O, Jap PHK, Vooijs GP. Coexpression of keratin- and vimentin-type intermediate filaments in human metastatic carcinoma. *Proc Natl Acad Sci USA* 1983;80:2618-22.
23. Ramaekers FCS, Puts JJG, Kant A, Moesker O, Jap PHK, Vooijs GP. Use of antibodies to intermediate filaments in the characterization of human tumors. *Cold Spring Harbor Symp Quant Biol* 1981;46:331-9.
24. Ramaekers F, Puts J, Kant A, Moesker O, Jap P, Vooijs P. Differential diagnosis of human carcinomas, sarcomas, and their metastases using antibodies to intermediate-sized filaments. *Eur J Cancer Clin Oncol* 1982;18:1251-7.
25. Ramaekers FCS, Puts JJG, Moesker O, et al. Antibodies to intermediate filament proteins in the immunohistochemical identification of human tumours: an overview. *Histochem J* 1983;15:691-713.
26. Ramaekers F, Puts J, Moesker O, Kant A, Jap P, Vooijs P. Demonstration of keratin in human adenocarcinomas. *Am J Pathol* 1983;111:213-23.
27. Böck P. Langerhans cells in the epithelium of main pancreatic ducts. *J Submicrosc Cytol* 1983;15:865-72.

Villous Adenoma Associated with A History of Immunosuppression

Helen M. ...

Departments of Pathology and ...

Summary: An unusual villous adenoma of the uterine cervix. Microscopic features, immunohistochemical staining, and immunofluorescent evidence are presented. The association of villous adenoma with immunosuppression is discussed. **Key Words:** Villous adenoma, immunosuppression, uterine cervix.

Villous adenomas are potential for malignant transformation of the gastrointestinal tract and urinary bladder. In a case of villous adenoma of the uterine cervix, immunofluorescent evidence of differentiation in the villi is presented. On the edge, this case represents a potential for malignant transformation of the body. It also suggests a potential for malignant transformation of the uterine cervix.

A 32-year-old multiparous woman was admitted to the Medical Center at the University of ... mucorrhoea and a cervix.

Address correspondence to: J. J. G. Puts, M.D., Department of Pathology, University Hospital ...